



ANATOMICAL VARIATIONS OF THYROID GLAND AND ITS CLINICAL SIGNIFICANCE IN NORTH INDIAN POPULATION

*Dr. Hussein Muktyaz, **Dr. Yadav Birendra, ***Dr. Saxena Dhiraj & ****Dr. Sharma Kr. Arun

*Assistant Professor, Department of Anatomy, Govt. Medical College Ambedkar Nagar, U.P. India.

**Assistant Professor, Department of Physiology, Govt. Medical College Ambedkar Nagar, U.P. India.

***Associate Professor, Department of Anatomy, S.M.S. Medical College, Jaipur, Rajasthan, India.

****Lecturer, Department of Anatomy, Govt. Medical College Ambedkar Nagar, U.P. India.

Abstract

Thyroid gland lies deep to the sternothyroid and sternohyoid muscles, located anteriorly in the neck at the level of the 5th cervical to first thoracic vertebrae. Accessory nodules/ ectopic thyroid tissues are usually present at the embryonic origin of thyroid gland, at the foramen caecum, or on the lingual duct and thyroglossal tract within the tongue. The morphological variations are usually diagnosed incidentally during examination for other thyroid gland diseases; therefore the true incidence is uncertain. This study was structured to investigate the gross anatomical features of the thyroid gland in 56 cadavers (41 males and 15 females) from the North Indian population at Govt. Medical College, Ambedkar Nagar U.P. and S.R.M.S. Institute of Medical Sciences, Bareilly U.P. In our study we observed pyramidal lobe in (41.0%), levator glandular thyroideae (19.6%), absence of isthmus in (12.5%) and one case (3.5%) accessory thyroid tissue was found out of 56 cadavers. This study highlights the various developmental anomalies of the thyroid gland, which forms a cornerstone for safe and effective surgery.

Key Words: *morphological variations, thyroid gland, levator glandulae thyroideae, pyramidal lobe, agenesis.*

Introduction

The anomalies of the development of thyroid gland distort the morphology of the gland and cause clinical functional disorders and various thyroid illnesses reported by Arriaga MA et al [1988]¹ and Melnick JC [1981]¹² Thyroid gland lies deep to the sternothyroid and sternohyoid muscles, located anteriorly in the neck at the level of the 5th cervical to first thoracic vertebrae.¹³ Accessory nodules/ ectopic thyroid tissue of the thyroid are usually found at the embryonic origin of thyroid gland, at the foramen caecum, or on the lingual duct and thyroglossal tract within the tongue studied by Bergman RA [2004]³ Moreover these accessory thyroid tissue of the thyroid are also seen at various other sites of body like anterior mediastinum reported by Sand J et al [1996]¹⁵ in heart by Casanova JB et al [2000]⁵ lung by Bando T [1993].² These ectopic thyroid tissues may later undergo malignant changes studied by Sand J et al [1996]⁶ and Hari CK [1999]⁷ Approximately 50% of thyroid glands have a pyramidal lobe. This lobe, which varies in size, extends superiorly from the isthmus of the thyroid gland, usually to the left of the median plane; the isthmus may be incomplete reported by Moore KL [2006].¹³ A band of connective tissue may continue from the apex of the pyramidal lobe to the hyoid. The pyramidal lobe and the band develop form remnants of the epithelium and connective tissue of the thyroglossal duct.¹³ The aim of present study is to highlight morphological variations and various developmental anomalies of the thyroid gland in North Indian population and compare it with the normal thyroid gland (Figure.1), thereby forming a cornerstone to safe and effective surgery.

Materials and Methods

In the present study observations were made on cadavers while they were used for routine dissection classes for medical undergraduate students over a period of four years. Dissections were performed on the neck region of 56 cadavers of both sexes (41 male and 15 female) in the department of anatomy Govt. Medical College Ambedkar Nagar and S.R.M.S. Institute of Medical Sciences Bareilly U.P. India. The thyroid gland was exposed according to Cunningham's practical manual of anatomy and studied for any variations and developmental anomalies including partial and total agenesis of the gland, presence of ectopic tissues or accessory thyroids, permanent thyroglossal duct anomalies such as cyst, fistula, sinus, and pyramidal lobe or fibrous band were observed. The specimens were photographed and the findings were appropriately documented.

Results

The anatomical variations observed in present study out of 56 cadavers were presence of pyramidal lobe in (41.0%) 23 male cadavers (Figure. 2) and pyramidal lobe was absent in female cadavers, presence of levator glandular thyroideae (19.6%) 11 cadavers among them only 2 female cadavers (3.5%) showed presence of levator glandular thyroideae (Figure. 3). Absence of isthmus (12.5%) 07 cadavers of which 02 were female cadavers (3.5%) (Figure. 4). In two cases (3.5%) accessory thyroid tissue was found above the cricoid cartilage as a separate mass supplied by the branch of superior thyroid artery (Figure. 5) and after histological study found accessory tissue was thyroid tissue. The incidence of thyroid gland variations shown in table 1.

Table: 1

Percentage incidence of thyroid gland variations out of 56 cadavers.

S.No.	Types of variation	No. of Cadavers	Percentage (%)
1.	Pyramidal lobe	23	41.0%
2.	Levator glandular thyroideae	11	19.6%
3.	Absence of isthmus	07	12.5%
4.	Accessory thyroid tissue	2	3.5%

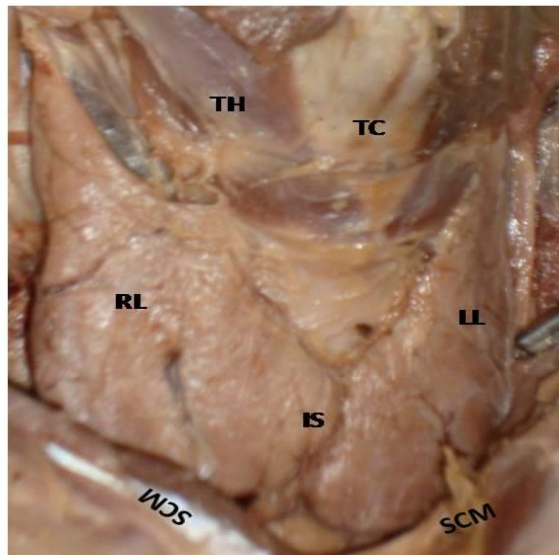


Figure 1: Photograph of front of the neck showing normal thyroid gland.(RL:Right Lobe; LL:Left Lobe; IS: Isthmus; SCM: Sternocleidomastoid Muscle; TH:Thyrohyoid Muscle; TC: Thyroid Cartilage)

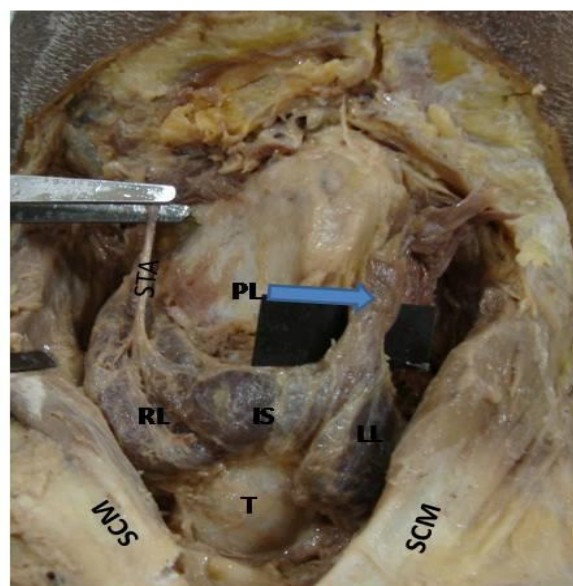


Figure 2: Photograph of front of the neck showing pyramidal lobe with arrow. (RL:Right Lobe; LL:Left Lobe; IS: Isthmus; SCM:Sternocleidomastoid Muscle; STA: Superior Thyroid Artery; T: Trachea)

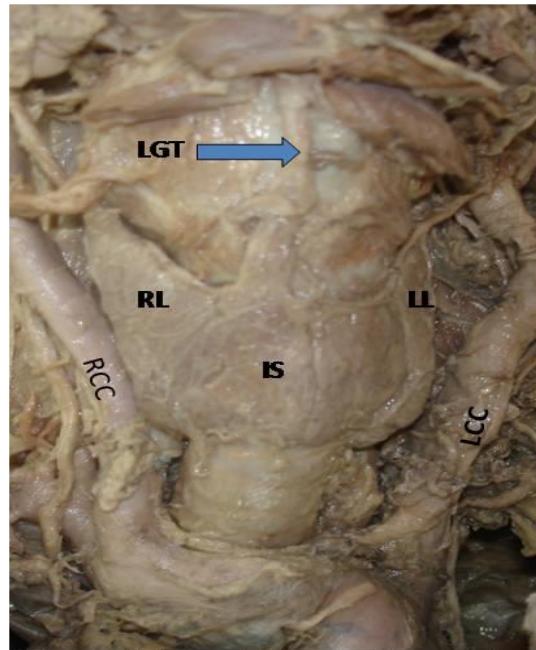


Figure 3: Photograph of front of the neck showing levator glandulae thyroideae (LGT) with arrow. (RL:Right Lobe; LL:Left Lobe; IS: Isthmus; RCC:Right Common Carotid Artery;LCC: Left Common Carotid Artery)

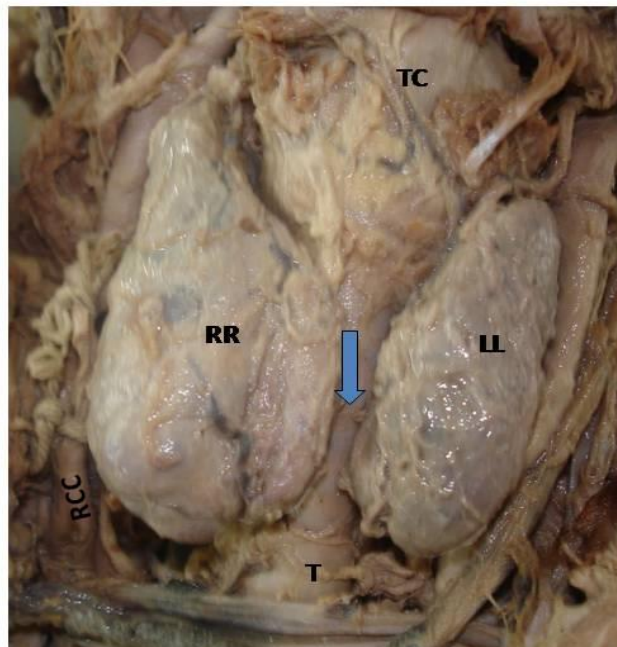


Figure: 4 Photograph of front of the neck showing absence of isthmus with arrow. (RL:Right Lobe; LL:Left Lobe; RCC:Right Common Carotid Artery; TC:Thyroid Cartilage;T: Trachea)

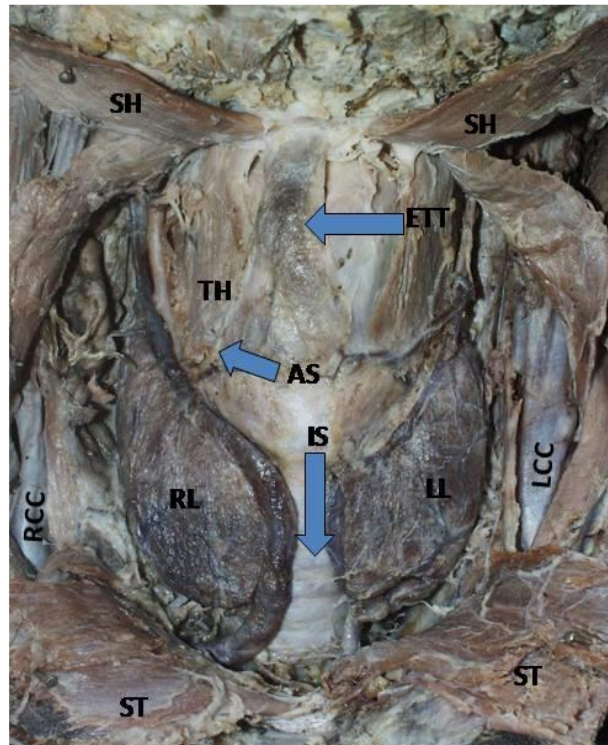


Figure: 5 Photograph of front of neck showing ectopic thyroid tissue(ETT), absence of isthmus (IS) and arterial supply (AS) of ectopic tissue with arrow. (RL:Right Lobe; LL: Left Lobe;RCC: Right Common Carotid Artery; LCC:Left Common Carotid Artery; TH:Thyrohyoid Muscle; SH:Suprahyoid Muscle; ST: Sternothyroid Muscle)

Discussion

Thyroid disorder is a common health problem among large number of endocrinopathies. About 5% of the world population is affected from various thyroid diseases. Most of the diseases affecting the thyroid gland e.g. goitre, thyrotoxicosis, adenoma, carcinoma etc. are usually associated with enlargement of the gland and require medical and surgical intervention studied by Strachan MWJ [2006]¹⁷. Most of the variations of the thyroid gland are due to a partial persistence of the median or thyroglossal duct by Melnick JC et al [1981]¹². This study describes variations and developmental anomalies including partial and total agenesis of the gland, presence of ectopic tissues or accessory thyroids, permanent thyroglossal duct anomalies such as cyst, fistula, sinus, and pyramidal lobe or fibrous band. Developmental failure of all or part of the gland resulting in agenesis or hemi-agenesis, that may be unilateral or isthmic at a normal location may occur by Kaplaw EL et al [1994]⁹. Many workers claim that the absence of isthmus is quite rare in the human by Larochelle D et al [1979]¹⁰ and in adult animals the isthmus is either present or absent. The isthmus was missing in four cases of the 58 cadavers studied by Braun et al [2007].⁴ Pyramidal lobes could be a source of pitfalls in thyroidectomy, due to its frequency by unreliable preoperative diagnosis on scintigraphic images. A pyramidal lobe was found to be present in 55% of the cadavers.¹² In a study performed to clarify the morphologic characteristics of the thyroid glands in Koreans [2002]¹⁸ the frequency of the existence of the pyramidal lobe was 76.8%.

The possible origin of the ectopic thyroid tissue in the parotid salivary gland could be due to a common evolution of the thyroid and parathyroid glands, a heteroplasia or a metaplasia Mysorekar et al [2004].¹⁴ Soemmerring [1794]¹⁶ described the levator glandular thyroidae as an accessory muscle which ran from the hyoid bone to insert partly on the thyroid cartilage and partly on the isthmus of the thyroid gland. The size and shape of the thyroid gland may alter remarkably with age, gender, physiological condition, race, and geographical location. It may be larger and heavier in females than in males, and it hypertrophies during menstruation and pregnancy reported by Fakhrul AHB et al [2010]⁶. J.F. Pastor Vázquez [2006]⁸ describe a case of thyroid isthmus agenesis (the incidence varies from 5% to 10%). This absence can be explained as an anomaly of embryological development and can be associated with other types of disorganogenesis, such as the absence of a lobe or the presence of ectopic thyroid tissue. M J Phukon R Dutta et al reported [2012]¹¹, the thyroid gland was observed to be consisting of a pyramidal lobe arising from its right side. A levator glandulae thyroidae extended from the apex of the pyramidal lobe to the hyoid bone. In this case, the isthmus is not present at the normal level i.e. 2nd to 4th tracheal rings.

Conclusion

Knowledge of anatomical variations of thyroid gland is essential for routine surgical procedure of thyroid. Proper identification of thyroid gland vessels is very important in order to avoid major complications during and after neck surgeries. Thyroid anatomy and its associated anatomical variations are very essential to know for Endocrinologist and Surgeons, so that these anomalies are not overlooked while arriving at a diagnosis.

References

1. Arriaga MA, Myers EN (1988). Ectopic thyroid in the retro esophageal superior mediastinum. *Otolaryngol Head Neck Surg.*; 99: 338-40.
2. Bando T, Genka K, Ishikawa K, Kuniyoshi M, Kuda T (1993). Ectopic intrapulmonary thyroid. *Chest.*; 103:1278-9.
3. Bergman RA, Afifi AK, Miyauchi R (1992-2004). Thyroid gland illustrated encyclopedia of human anatomic variation: Opus IV: Organ system: Endocrine System.
4. Braun E, Windisch G, Wolf G, Hausleitner L, Anderhuber F (2007). The pyramidal lobe: Clinical anatomy and its importance in thyroid surgery. *Surg and Radiol Anat.*; 29 (1): 21-7.
5. Casanova JB, Daly RC, Edwards BS, Tazelaar HD, Thompson GB (2000). Intracardiac ectopic thyroid. *Ann Thorac Surg.*; 70:1694-6.
6. Fakhrul AHB, Zakia S, Mansur K, Seheli ZS, Sheikh MAB, Abdul Q, Fashiru R (2006). Weight and volume of whole thyroid gland in Bangladeshi people: a postmortem study. *Bangladesh J Anat* 8: 72–75.
7. Hari CK, Brown MJ, Thompson I (1999). Tall cell variant of papillary carcinoma arising from ectopic thyroid tissue in the trachea. *J Laryngol Otol.*; 113: 183-5.
8. J.F. Pastor Vázquez, J.A. Gil Verona, F.J. De Paz Fernández and M. Barbosa Cachorro (2006): Agenesis of the thyroid isthmus, *Eur J Anat*, 10 (2): 83-84.
9. Kaplaw EL, Shukla M, Hara H, Ito K. (1994). Developmental abnormalities of the thyroid. In: De Groot L J, ed. *Endocrinology*, Philadelphia: Saunders 893-9.
10. Larochelle D, Arcand P, Belzile M, Gagnon N- B (1979). Ectopic thyroid tissue- A review of the literature. *J Otolaryngol*: 8: 523-30.
11. M J Phukon R Dutta, G N Reddy , P Bhargabhi , N A Syed (2012); Right Sided Pyramidal Lobe of Thyroid Gland- A Case Report, *Int J Biol Med Res.*; 3(2): 1839 – 1841.
12. Melnick JC, Stemkowski PE (1981). Thyroid hemi-agenesis (Hockey stick sign): A review of the world literature and a report of four cases. *J Clin. Endocrinol, Metab*; 52 (2): 247-51.
13. Moore KL, Dalley AF (2006). *Clinically oriented anatomy* 5th ed. Lippincott Williams- Wilkins Pp.1083-5.
14. Mysorekar VV, Dandekar CP, Sreevathsa MR (2004). Ectopic thyroid tissue in the parotid salivary gland. *Singapore Med J.*; 45 (9): 437.
15. Sand J, Pehkonen E, Mattila J, Seppanen S, Salmi J (1996). Pulsating mass at the sternum: a primary carcinoma of ectopic mediastinal thyroid. *J Thorac Cardiovasc Surg.*; 112: 833-5.
16. Soemmerring ST (1794). *De muscularis, tendinibus ET buris mucosis*. Frankfurt is Main. Clossius ET Schreger pp 128.
17. Strachan MWJ (2006), Walker BR. Endocrine disease. In: Boon NA, Colledge NR, Walker BR, Hunter JAA. Eds. *Davidson's principles and practice of medicine*. 20th Ed. New Delhi: Elsevier Churchill Livingstone; p. 744-62.
18. Won HS, Chung IH (2002). Morphologic variations of the thyroid gland in Korean adults. *Korean J Phys Antropol.*; 15 (2): 119-25.