



THE TOXICITY STUDY OF ETHANOLIC LEAF EXTRACT OF SESAMUM INDICUM ON THE HISTOMORPHOLOGY OF THE LIVER OF ADULT WISTAR RATS

Kelechi C. Uruakpa¹, Kebe E. Obeten², Eru, M. Eru³, & Anozeng O. Igiri⁴

Department of Anatomy, University of Calabar, Calabar-Nigeria

ABSTRACT

The aim of this work was to assess the toxic effect of ethanolic leaf extract of *Sesamum indicum* on the histomorphology of the liver of adult Wistar rats. Forty five Wistar rats weighing between 150-180g were divided into three groups of fifteen each (A, B and C). the rats in group A were taken as control and given distilled water, experimental groups B and C received 200mg/kg and 400mg/kg of the leaf extract respectively. The extract was administered for two weeks at the end of which the animals were sacrificed. The kidneys were harvested and processed for H&E staining method. From the results obtained, the administration of ethanol leaf extract of *Sesamum indicum* caused an ephased architectural pattern with atrophic hepatocytes and dilated sinusoid. This effect is attributed to sesamin content of *Sesamum indicum* and thus suggest that the extract may be toxic to the liver of Wistar rats.

Keywords: Liver, *Sesamum indicum*, Microanatomy, Wistar rats, Toxic.

1. Introduction

Medicinal plants are relevant in both the developed and developing nations of the world as sources of drugs or herbal extracts for chemotherapeutic purposes. Medicinal plants are relevant in both the developed and developing nations of the world as sources of drugs or herbal extracts for chemotherapeutic purposes. Also the use of plant derived herbal compounds as part of herbal preparations as alternative sources of medication continues to play major roles in the general wellness of people all over the world (Farombi,2003).

Aside the usual nourishment these plant products provide, they have been confirmed to serve medicinal functions. Traditionally, they are used as remedies for certain ill conditions and for the management of some ailments. Nevertheless, these medicinal plants have been confirmed to have various effects on the internal organs of the body.

In the southwest and middle belt areas of Nigeria, one of these medicinal plants *Sesamum indicum* is widely used as herbal remedies for the treatment of various ailments like infantile cholera, diarrhea and urinary infections (Chakraborty *et al*, 2008).

Sesamum indicum is a flowering plant in the genus *Sesamum* and family *padaliaceae*. It has numerous wild relatives in Africa and smaller number in India. *Sesamum indicum* is commonly known as Sesame in English, Benne seed in Bantu, Isisa in Igbo, Ridi in Hausa, Ekuku in Yoruba and Kana in Obudu. It is a plant known for its therapeutic values (Morebise *et al*, 2002). Medically, some studies have also shown that sesame leaves and seeds are used for medicinal purposes as it been found that the leaves are rich in a gummy matter and when mixed with water, they form rich blend mucilage which is used in the treatment of infant cholera, diarrhea, dysentery, catarrh and bladder problems (Beckstrom-Sternberg *et al*, 1994; Moerman, 1998; Brown, 1995; Allardice, 1993).

The kidneys chief responsibility is urine production. Here, blood is delivered through the renal arteries and is filtered through the kidneys, where harmful waste products are removed, notably ammonia and urea. The urine is concentrated and what results is a solution that is carried to and stored within the bladder prior to excretion (Kriz and Kaissling, 2005). Urine production is not the kidneys only function. Its plays a vital role in maintaining homeostasis of water and electrolyte, regulation of acid-base balance, regulation of arterial pressure, secretion, metabolism and excretion of hormones and gluconeogenesis (Guyton and Hall, 2011).

Functionally, the organs affect the formation and secretion of urine, production and secretion of erythropoietin, the hormone responsible for controlling the rate of formation of red blood cells, the hormone responsible for controlling renin, an important enzyme in the control of blood pressure (Gannon, 2006). They also function in the removal of waste products of metabolism and excess of water and salts from the blood and maintain its PH (Chaurasia, 2010).

2. Materials and Method

Forty-five adult Wistar rats weighing about 150-180g were used for this research work. They were housed in cages made of wire gauze in the animal house of the department of Human Anatomy, Faculty of Basic Medical Sciences, University of Calabar. They were brought from the animal house of Zoology department, university of Calabar and acclimatized in their various cages for a period of two weeks before commencement of the treatment. The animals were housed under standard conditions with 12 hours light /12 hours dark cycle throughout the duration of the experiment. The animal house was kept in good sanitary condition so as to enhance the well being of the animals. They were fed with rat chow produced by vital feeds Nigeria Limited, Lagos and water was provided ad-libitum. The animals were weighed using a beam balance(OHAUS- PAT.No.2.729.439) before and after the experiment. The weights of the animals were

used as criteria for grouping the animals into the different experimental groups while the animals used as control were randomly selected.

2.1. Extract preparation and administration

The extract used for this research was got from fresh *Sesamum indicum* leaves obtained from Yakkurr Local government area of cross river state, Nigeria and authenticated by the Herbarium unit of Botany Department, University of Calabar. The leaves were plucked, washed to remove debris and air-dried at room temperature. They were blended to a fine powder using a blender. The blended sample of *Sesamum indicum* (leaf) powder was weighed using digital weighing balance and was found to weigh 105g. The extraction of the active ingredients in the *Sesamum indicum* (leaves) was done using soxhlet extractor. The blended sample was soaked in 2 litres of 98% ethanol for 48hours. The extract was filtered into a beaker using Whatman No.1 filter paper and concentrated to dryness using rotary evaporator. The volume of the extract was weighed and found to be 19.7g. The extract so obtained was stored in the refrigerator for preservation.

The animals were grouped as follows:

Group A: Control (Distilled water- 1ml).

Group B: Leaf extract 200mg/kg (36mg/ml/170g rat)

Group C: Leaf extract 400mg/kg (72mg/ml/170g rat)

2.2. Termination of experiment

At the end of the two weeks period, the animals in all the groups were sacrificed under chloroform anesthesia. The kidneys of each animal were removed and washed with normal saline and processed through paraffin sections for Heamatoxylin and eosin (H&E).

3. Results

3.1. Effects of extracts on the body weight

The mean body weights of the groups of the animals administered leaf extract of *Sesamum indicum* before and at the end of the experimental periods are shown in fig. 1 below with the final mean weights of the groups showing $188.00 \pm 3.74\text{g}$ for the control group as against its initial mean body weight of $184.00 \pm 2.45\text{g}$ while the groups B (Low dose) and C (high dose) showed $182.00 \pm 2.00\text{g}$ and $192.00 \pm 7.35\text{g}$ as their final mean body weight, as against their initial mean body weights of $178.00 \pm 2.00\text{g}$ and $187.00 \pm 4.36\text{g}$ respectively.

The mean body weight change for the groups administered at leaf extract showed no significant difference when compared with the control as shown in figure 1.

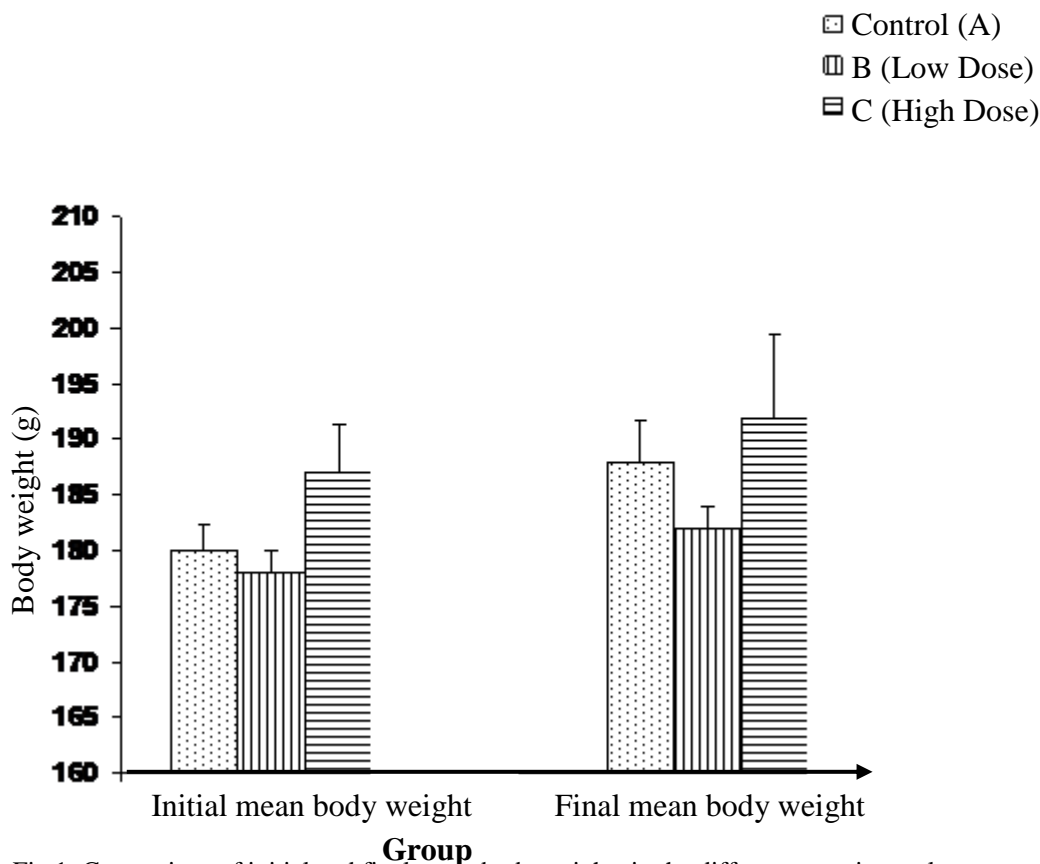


Fig 1: Comparison of initial and final mean body weights in the different experimental groups with control

3.2. Histological Analysis

3.2.1. Effects of extracts on the kidney

Plate I shows the photomicrograph of a section of the kidney tissues from animals which served as control showing normal histological features of the kidney. This shows the renal corpuscles (RC) of the cortex composed of the glomerulus (G) within the Bowman's capsule. The Bowman's capsule is lined by thin layer of single squamous cells. The proximal (PCT) and distal convoluted tubules (DCT) are lined by single layer of cuboidal epithelium. The Bowman's space (BS) is also present.

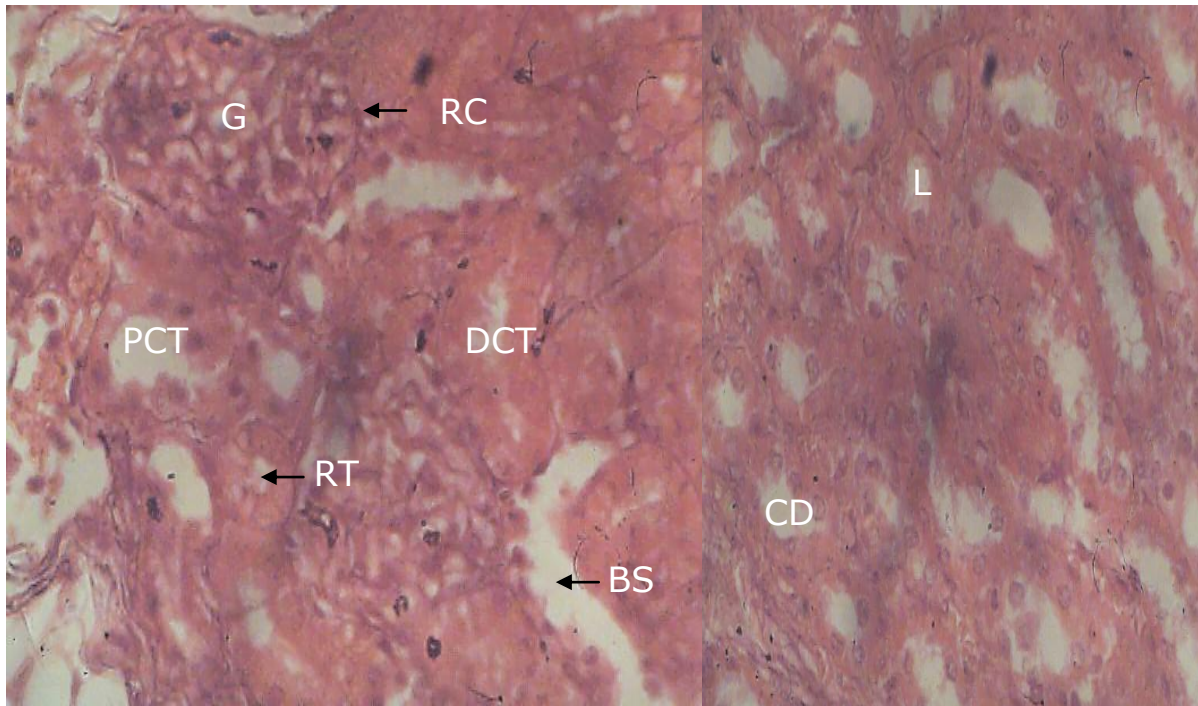


Plate 1: Control Kidney (Cortex and medulla)

Section of the kidney from rat given distilled water for 14 days using H&E stain, (X400) reveals the renal corpuscles composed of the glomerulus (G) within the Bowman's capsule (BS). The DCT and PCT appearing distinct.

Plate 2 shows a photomicrograph of section of kidney from the group of animals which received the low dose of the leaf extract 200mg/kg body weight of leaf extract. This showed hypertrophy of the tubular cells and the glomerulus also appearing edematous.

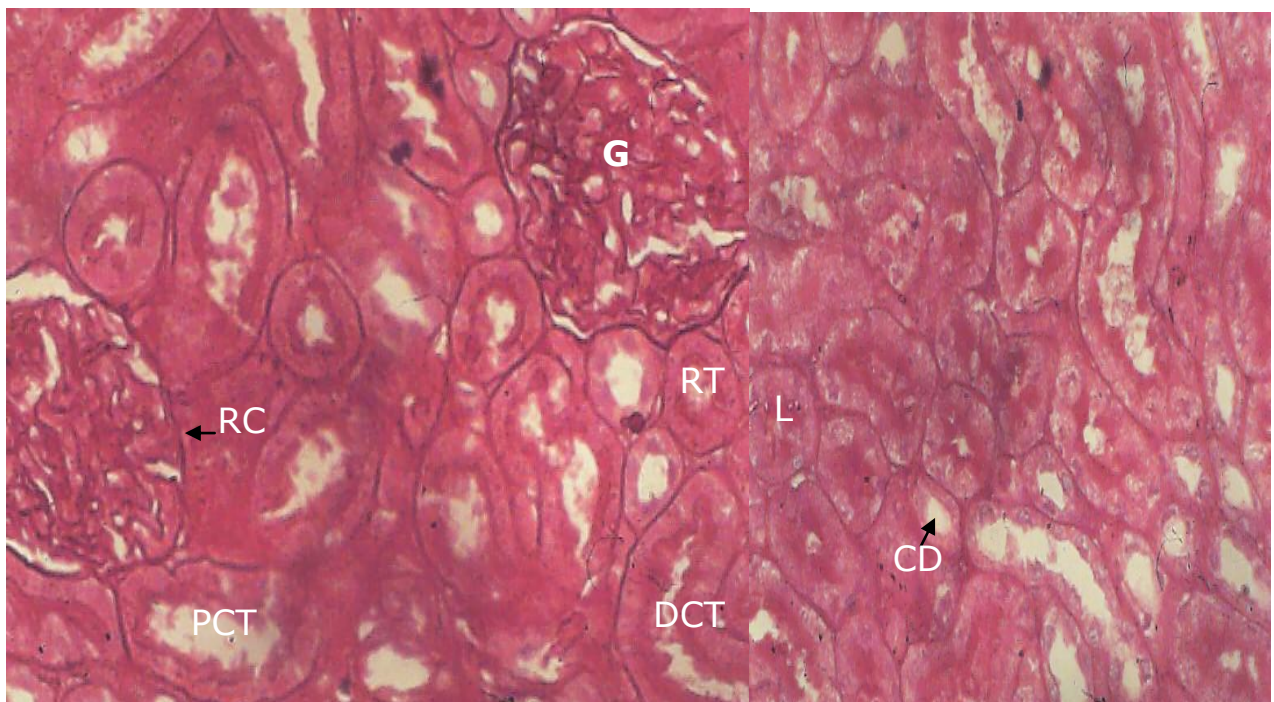


Plate 2: Photomicrograph of kidney (cortex and medulla) of rat fed with 200mg/kg of leaf extract of SI using H&E stain (X400) shows hypertrophy of the tubular cells and edematous glomerulus.

Plate 3 is a photomicrograph of a section of the kidney tissue from the animals treated with 400mg/kg body weight of leaf extract showing the glomerulus with larger urinary space (Dilatation) and edematous cells.

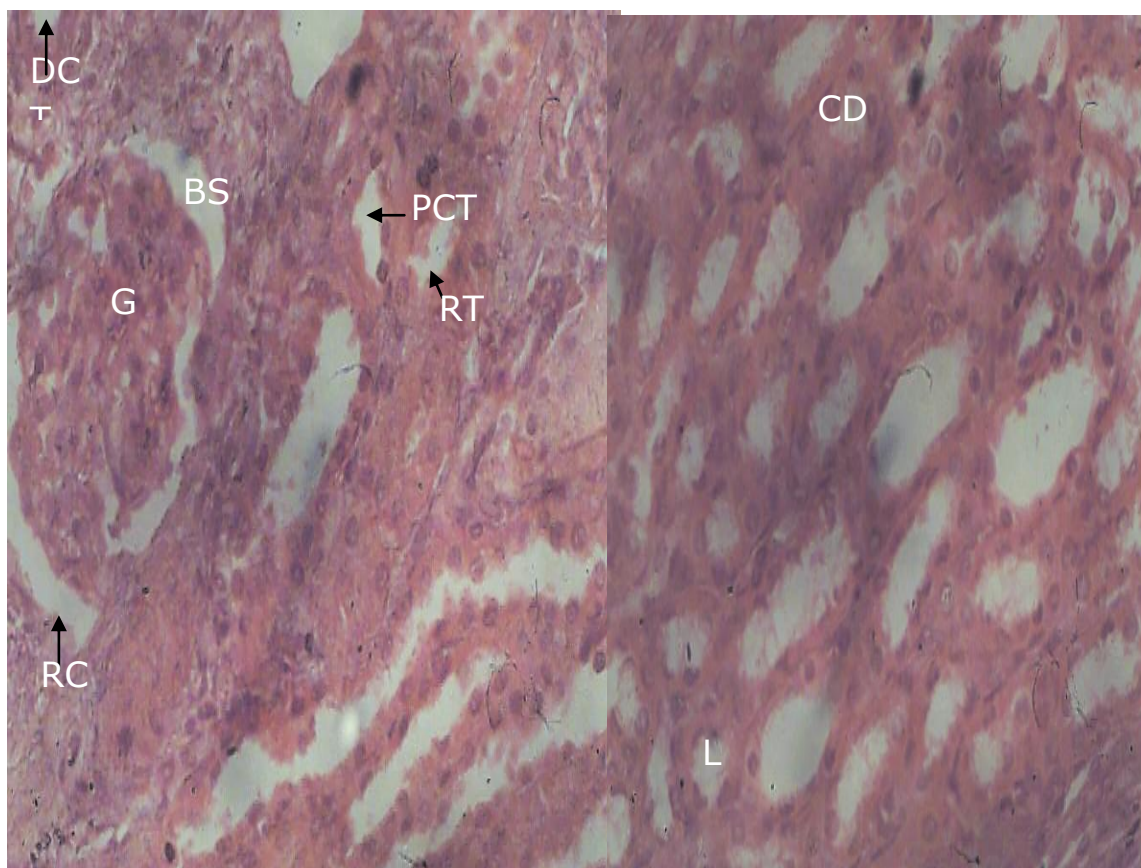


Plate 3: Photomicrograph of kidney (cortex and medulla) of rat fed with 400mg/kg of leaf extract of SI using H&E stain (X400) shows dilated urinary space and edematous cells.

3.3. Discussion

Drugs are known to produce adverse effects under prolonged and continuous usage. Although a drug may be very effective in the treatment of an illness but the effects of these drugs on some vital organs could necessitate its withdrawal from circulation.

Sesamum indicum is one of the most useful traditional medicinal plants known in Nigeria for its therapeutic value (Bedigian 1985, Ashri 1989).

The administration of ethanolic leaf of *sesamum indicum* caused hypertrophy of the tubular cells and an oedema of the glomerulus in the group treated with 200mg/kgBW of the leaf extract, while the administration of 400mg/kgBW of the same leaf extract caused an enlargement of the urinary space (Dilatation) and some edematous cells, which show that the administration of the ethanolic leaf extract of *sesamum indicum* had some nephrotoxic effect on the morphology of the kidney. This could be due to the sesamin content of *sesamum indicum* which could be seen to have an insecticidal effect on the kidney. The administration of leaf extract caused some pathological changes in the liver as it showed an ephased architectural pattern with degenerated atrophic hepatocytes with pyknotic nuclei in both groups treated with 200mg/kgBW and 400mg/kgBW. This suggests that the extract could induce hepatotoxicity.

4. Conclusion

The results of this experimental work using animal models may not be used to give direct application in man but it gives an insight into the possible toxic effects of the substance. From the results obtained from the study, it could be deduced that, the administration of ethanolic leaf extract showed some toxicity to the kidney cells in the rats.

References

- Allardice, P (1993) A – Z of companion planting cassel publishers limited.
- Beckstrom-Sternberg, S . M and Duke ,J.A (1994). The phytochemical Database. <http://arsgenome.cornell.edu/cgibin/webace=phtochemab> (Data version).
- Bedigian D. Seigher D & Harlan J. R (1985) Sesamin, Sesamolin and the origin of Sesame. *Biochemistry systematic Ecology*. 13; 133-139.
- Brown, D (1995) Encyclopedia of herbs and there uses. Dorling Kindersley, London.
- Charkraborty G. S, Sharma G, & Kaushi K. N (2008) *Journal of Herbal Medicine and Toxicology*, 2 (2); 5-19.
- Chaurasia B .D (2011) Human Anatomy;Regional and Applied Dissection and Clinical.(5th) 288-299.CBS publishers & Distributors, New Dehli

- Farombi, E.O (2003). African Indigenous plant with chemotherapeutic potentials and biotechnological plants with production of bioactive prophylactic agents. *African Journal of Biotechnology*. 2(12) 662-671
- Gannon, W.F (2003) Review of medical physiology (21st ed) London; Lange.
- Guyton, A.C and Hall, J.E (2011). *Endocrinology and reproduction*. Textbook of Medical Physiology. London (12 eds)1034 -1042
- Kriz, W and Kaissling, B, (2005). *Structural organization of the mammalian kidney*. In *seldin DW, Giebisch G (eds)*. The kidney–physiology and pathophysiology, 4th ed. New York; Raven press,687-705.
- Moerman, D (1998) Native American Ethnobotany. Timber press. Oregon
- Morebise, O., Fafunso, M.A & Makinde, M.J (2002) *Sesame or Flax?* Bulletin on Sumerian Agriculture 2; 159-178.